

MANAGEMENT OF SEVERE MALARIA

A practical handbook

Second edition



World Health Organization
Geneva

The World Health Organization was established in 1948 as a specialized agency of the United Nations serving as the directing and coordinating authority for international health matters and public health. One of WHO's constitutional functions is to provide objective and reliable information and advice in the field of human health, a responsibility that it fulfils in part through its extensive programme of publications.

The Organization seeks through its publications to support national health strategies and address the most pressing public health concerns of populations around the world. To respond to the needs of Member States at all levels of development, WHO publishes practical manuals, handbooks and training material for specific categories of health workers; internationally applicable guidelines and standards; reviews and analyses of health policies, programmes and research; and state-of-the-art consensus reports that offer technical advice and recommendations for decision-makers. These books are closely tied to the Organization's priority activities, encompassing disease prevention and control, the development of equitable health systems based on primary health care, and health promotion for individuals and communities. Progress towards better health for all also demands the global dissemination and exchange of information that draws on the knowledge and experience of all WHO's Member countries and the collaboration of world leaders in public health and the biomedical sciences.

To ensure the widest possible availability of authoritative information and guidance on health matters, WHO secures the broad international distribution of its publications and encourages their translation and adaptation. By helping to promote and protect health and prevent and control disease throughout the world, WHO's books contribute to achieving the Organization's principal objective – the attainment by all people of the highest possible level of health.

Table 1 Antimalarial chemotherapy of severe falciparum malaria

Chloroquine-resistant malaria or sensitivity not known

Quinine (adults): 20 mg dihydrochloride salt/kg of body weight (loading dose)¹ diluted in 10 ml isotonic fluid/kg by IV infusion over 4 hours; then 8 hours after the start of the loading dose, give a maintenance dose of quinine, 10 mg salt/kg, over 4 hours. This maintenance dose should be repeated every 8 hours, calculated from the beginning of the previous infusion, until the patient can swallow, then quinine tablets, 10 mg salt/kg, 8-hourly to complete a 7-day course of treatment, or a single dose of 25 mg/kg sulfadoxine and 1.25 mg/kg pyrimethamine (maximum 1500 mg sulfadoxine–75 mg pyrimethamine).

Quinine (children): 20 mg dihydrochloride salt/kg (loading dose)¹ diluted in 10 ml isotonic fluid/kg by IV infusion over 4 hours; then 12 hours after the start of the loading dose, give a maintenance dose of quinine, 10 mg salt/kg, over 2 hours. This maintenance dose should be repeated every 12 hours, calculated from the beginning of the previous infusion, until the patient can swallow, then quinine tablets, 10 mg salt/kg, 8-hourly to complete a 7-day course of treatment, or a single dose of 25 mg/kg sulfadoxine and 1.25 mg/kg pyrimethamine.

N.B. If IV infusion is not possible, quinine can be given IM (see important points, opposite); alternatively, consider artemisinin/artesunate suppositories.

or

Artesunate²: 2.4 mg/kg (loading dose) IV, followed by 1.2 mg/kg at 12 and 24 hours, then 1.2 mg/kg daily for 6 days. If the patient is able to swallow, the daily dose can be given orally.

or

Artemether: 3.2 mg/kg (loading dose) IM, followed by 1.6 mg/kg daily for 6 days. If the patient is able to swallow, the daily dose can be given orally.

N.B. If parenteral administration is not possible, artemisinin or artesunate suppositories may be given.

Artemisinin suppositories: 40 mg/kg (loading dose) intrarectally, then 20 mg/kg 24, 48 and 72 hours later, followed by an oral antimalarial drug.³

or

Artesunate suppositories: 200 mg intrarectally at 0, 12, 24, 36, 48 and 60 hours may prove to be highly effective and is in trial. A loading dose of 4 mg/kg intrarectally, followed by 2 mg/kg at 4, 12, 48 and 72 hours has been used in Viet Nam. This treatment should be followed by an oral antimalarial drug.³

As a last resort, if parenteral quinine, artemisinin, or artesunate is not available:

Quinidine: 15 mg base/kg (loading dose) by IV infusion over 4 hours, then 8 hours after the start of the loading dose, give 7.5 mg base/kg over 4 hours, 8-hourly, until the patient can swallow, then quinine tablets (dosage as above for adults and children) to complete a 7-day course of treatment, or a single dose of 25 mg/kg sulfadoxine and 1.25 mg/kg pyrimethamine.

Chloroquine-sensitive malaria

Chloroquine: 10 mg base/kg in isotonic fluid by constant-rate IV infusion over 8 hours, followed by 15 mg/kg given over the next 24 hours.

or

Chloroquine: 5 mg base/kg in isotonic fluid by constant-rate IV infusion over 6 hours, every 6 hours, for a total of 5 doses (i.e. 25 mg base/kg continuously over 30 hours).

or

(If IV infusion is not possible) chloroquine, 3.5 mg base/kg, every 6 hours IM or SC.⁴

or

Quinine or artemisinin derivative (see opposite).

¹ Alternatively, the loading dose can be administered as 7 mg salt/kg by IV infusion (or pump) over 30 minutes, followed immediately by 10 mg salt/kg diluted in 10 ml isotonic fluid/kg by IV infusion over 4 hours.

² Artesunic acid, 60 mg per ampoule, is dissolved in 0.6 ml of 5% sodium bicarbonate diluted to 3–5 ml with 5% dextrose and given immediately by IV bolus ("push") injection.

³ For example, mefloquine, 25 mg/kg in two divided doses 8–24 hours apart.

⁴ Total dose 25 mg base/kg; change to oral therapy when the patient can swallow.

Some important points to note about Table 1

In areas where a 7-day course of quinine is not curative (e.g. Thailand), add an oral course of tetracycline 4 mg/kg four times daily or doxycycline 3 mg/kg once daily, for 3–7 days, as soon as the patient can swallow (NOT in children under 8 years and pregnant women); or clindamycin 10 mg/kg twice a day, for 3–7 days, as soon as the patient can swallow.

If there is no clinical improvement after 48 hours of parenteral therapy, the maintenance dose of quinine or quinidine should be reduced by one-third to one-half (i.e. 5–7 mg quinine dihydrochloride/kg or 3.75–5 mg quinidine base/kg, 8-hourly).

Total daily doses of IV quinine in those patients who are not improving after 48 hours of parenteral therapy are as follows:

Adults: day 0 (first day of treatment): 30–40 mg salt/kg of body weight
day 1: 30 mg salt/kg of body weight
day 2 and subsequent days: 15–21 mg salt/kg of body weight

Children: day 0 (first day of treatment): 30–40 mg salt/kg of body weight
day 1: 20 mg salt/kg of body weight
day 2 and subsequent days: 10–14 mg salt/kg of body weight

It is unusual to have to continue IV infusions of quinine for more than 4–5 days. If it is more convenient, quinine may be given by continuous infusion. (Infusion rates should not exceed 5 mg salt/kg of body weight per hour.)

A loading dose of quinine should not be used if the patient has received quinine, quinidine or mefloquine within the preceding 12 hours.

If for some reason quinine cannot be administered by infusion, quinine dihydrochloride can be given in the same dosages by IM injection in the anterior thigh (*not* in the buttock). The dose of quinine should be divided between two sites – half the dose in each anterior thigh. If possible, for IM use, quinine should be diluted in normal saline to a concentration of 60–100 mg salt/ml.

Management of severe malaria

A practical handbook

Second edition



World Health Organization
Geneva 2000

First edition, 1991
Second edition, 2000

WHO Library Cataloguing-in-Publication data

Management of severe malaria : a practical handbook. – 2nd ed.

1.Malaria – complications 2.Malaria – therapy 3.Malaria – handbooks 4.Manuals

ISBN 92 4 154523 2 (NLM Classification: WC 39)

The World Health Organization welcomes requests for permission to reproduce or translate its publications, in part or in full. Applications and enquiries should be addressed to the Office of Publications, World Health Organization, 1211 Geneva 27, Switzerland, which will be glad to provide the latest information on any changes made to the text, plans for new editions, and reprints and translations already available.

© **World Health Organization 2000**

Publications of the World Health Organization enjoy copyright protection in accordance with the provisions of Protocol 2 of the Universal Copyright Convention. All rights reserved.

The designations employed and the presentation of the material in this publication do not imply the expression of any opinion whatsoever on the part of the Secretariat of the World Health Organization concerning the legal status of any country, territory, city or area or of its authorities, or concerning the delimitations of its frontiers or boundaries.

The mention of specific companies or of certain manufacturers' products does not imply that they are endorsed or recommended by the World Health Organization in preference to others of a similar nature that are not mentioned. Errors and omissions excepted, the names of proprietary products are distinguished by initial capital letters.

Designed by WHO Graphics
Printed in Malta
98/12060 – Interprint – 9000

Contents

Preface	v
----------------	----------

Introduction	1
---------------------	----------

Severe falciparum malaria	5
Who is at risk?	6

General management	7
Nursing care	10
Specific antimalarial chemotherapy	11

Clinical features and management of complications in adults	12
Cerebral malaria	12
Anaemia	16
Renal failure	16
Hypoglycaemia	17
Fluid and electrolyte disturbances	18
Pulmonary oedema	20
Circulatory collapse (“algid malaria”)	22
Abnormal bleeding and disseminated intravascular coagulation	23
High fever	24
Hyperparasitaemia	25
Malarial haemoglobinuria	25

Special clinical features of severe malaria and management of common complications in children	27
Severe malaria	27
Cerebral malaria	30
Anaemia	34
Respiratory distress (acidosis)	36
Hypoglycaemia	38
Dehydration	39
Antimalarial drugs	40

Special clinical features and management of severe malaria in pregnancy	41
Severe malaria	41
Hypoglycaemia	43
Pulmonary oedema	44
Anaemia	44
Antimalarial drugs	45

Diagnosis of malaria	46
Clinical diagnosis	46
Parasitological diagnosis	46
Haematological and biochemical findings	48

Prognostic indicators	49
------------------------------	-----------

Common errors in diagnosis and management	54
--	-----------

Selected further reading	56
---------------------------------	-----------

Annex 1. Notes on antimalarial drugs	57
---	-----------

Annex 2. The Glasgow coma scale	61
--	-----------

Annex 3. A coma scale for children	62
---	-----------

Annex 4. Cannulating the femoral vein	63
--	-----------

Annex 5. Setting up an intra-osseous infusion in children	65
--	-----------

Annex 6. Measurement of central venous pressure	68
--	-----------

Preface

Malaria continues to be a major global health problem, with over 40% of the world's population – more than 2400 million people – exposed to varying degrees of malaria risk in some 100 countries. In addition, with modern rapid means of travel, large numbers of people from nonmalarious areas are being exposed to infection which may only seriously affect them after they have returned home.

Plasmodium falciparum causes the most serious form of the disease, and is common in the tropics. Infections with this parasite can be fatal in the absence of prompt recognition of the disease and its complications, and urgent appropriate patient management. The situation is complicated by the increasing occurrence of *P. falciparum* parasites that are resistant to chloroquine and other antimalarial drugs. Prompt action is especially important for high-risk groups such as young children and pregnant women.

The increasing seriousness of this problem, and progress made in terms of how to manage this disease, prompted the World Health Organization to hold an informal technical meeting on severe malaria in 1995. As a result of these discussions and other recent developments, the practical handbook on *Management of severe and complicated malaria*, published by WHO in 1991, has been revised and updated, with some important changes being made. As before, the handbook is intended primarily for clinical professional staff and other responsible health personnel working in hospitals, or health centres with inpatient facilities, in malarious areas of the world. It is also intended for

physicians in non-endemic countries, who found the previous edition to be of great practical use.

The practical format of the original publication has been retained, but the section on childhood malaria has been expanded, based on new evidence from Africa. The recommendations for chemotherapy now include artemisinin derivatives. Comments, observations and suggestions for future editions will always be welcome.

During the revision of this practical handbook, advice and suggestions were provided by a number of colleagues. The World Health Organization gratefully acknowledges the valuable contribution made by Professor P.F. Beales, Faculty of Tropical Medicine, Mahidol University, Thailand; Professor D.A. Warrell, University of Oxford, England; Professor H.M. Gilles, Liverpool School of Tropical Medicine, England; Professor M.E. Molyneux, Liverpool School of Tropical Medicine, England; Professor N.J. White, Faculty of Tropical Medicine, Mahidol University, Thailand; Professor K. Marsh, Wellcome Trust Laboratories, Kenya Medical Research Institute (KEMRI), Kenya; Dr T.T. Hien, Centre for Tropical Diseases, Cho Quan Hospital, Ho Chi Minh City, Viet Nam; Dr B. Brabin, Liverpool School of Tropical Medicine, England; Dr E. Dorman, Wellcome Trust Laboratories, KEMRI, Kenya; and Dr C. Shulman, Wellcome Trust Laboratories, KEMRI, Kenya.

Technical contributions were made by Dr A. Bosman, World Health Organization, Geneva, Switzerland, Dr C. Delacollette, World Health Organization, Geneva, Switzerland, Dr P. Oliaro, United Nations Development Programme/World Bank/World Health Organization Special Programme for Research and Training in Tropical Diseases,

Geneva, Switzerland, Dr A. Schapira, World Health Organization, Viet Nam and Dr P. Trigg, World Health Organization, Geneva, Switzerland. Dr E. Renganathan and Dr F. Rio, World Health Organization, Geneva, Switzerland, had overall responsibility for preparation of the revised handbook, with administrative support from Mrs E.M. Jordan.

The World Health Organization thanks the World Bank which financially supported the development of this handbook.

■ Introduction

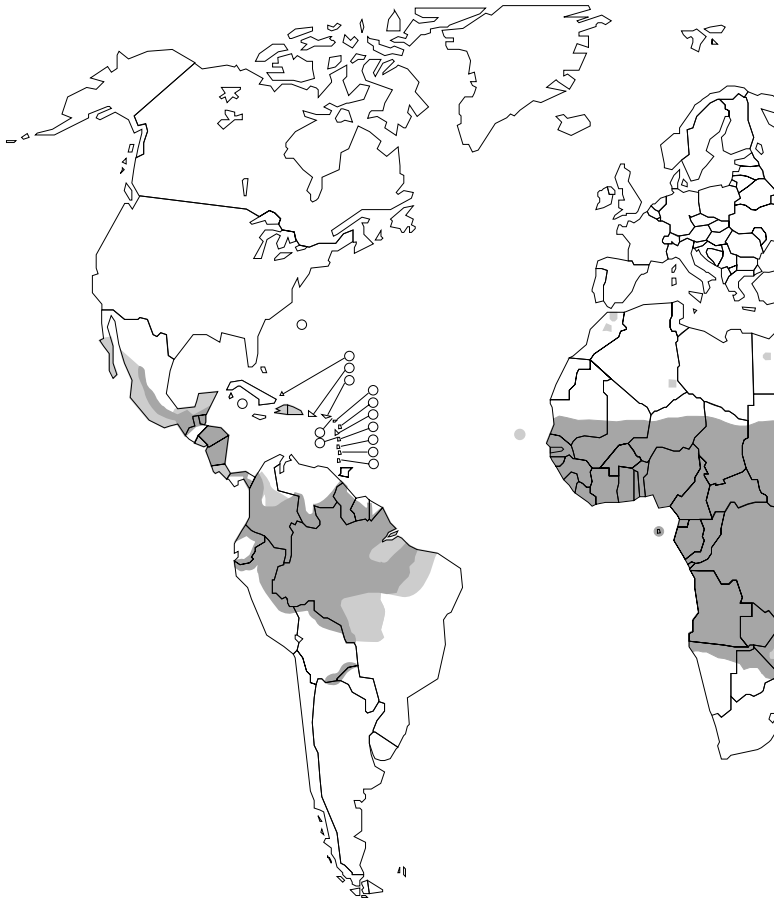
Severe malaria is caused by *Plasmodium falciparum* infection and usually occurs as a result of delay in treating an uncomplicated attack of falciparum malaria. Sometimes, however, especially in children, severe malaria may develop very rapidly. Recognizing and promptly treating uncomplicated *P. falciparum* malaria is therefore of vital importance. Global status of malaria is shown in Fig. 1.

Uncomplicated malaria

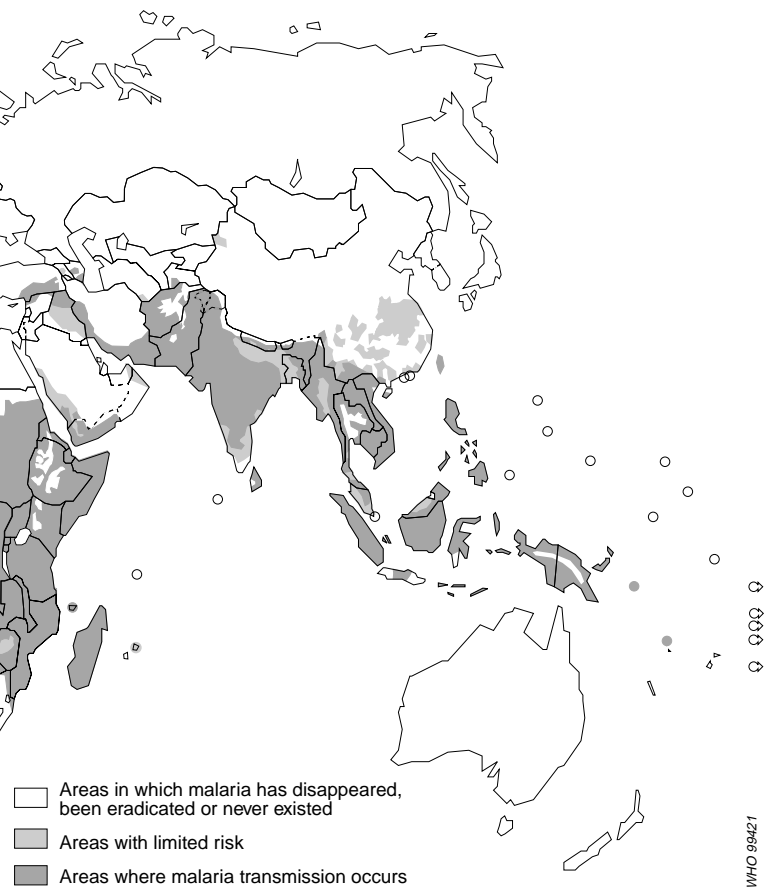
The presentation of uncomplicated *P. falciparum* malaria is very variable and mimics that of many other diseases. Although fever is common, it is absent in some cases. The fever is initially persistent rather than tertian (spikes of fever on alternate days, Fig. 2). The expectation that *P. falciparum* malaria should have a tertian fever pattern may lead to the diagnosis of malaria being missed with a consequent delay in treatment. The fever may or may not be accompanied by rigors. True rigors are relatively unusual in acute falciparum malaria.

The patient commonly complains of fever, headache, and aches and pains elsewhere in the body, and occasionally of abdominal pain and diarrhoea. In a young child there may be irritability, refusal to eat and vomiting. On physical examination fever may be the only sign. In some patients the liver and spleen are palpable. This clinical presentation in non-endemic or low-endemic areas may be misdiagnosed as influenza. Unless the condition is diagnosed and treated promptly the clinical picture may deteriorate at an alarming rate and often with catastrophic consequences.



Fig. 1. Global status of malaria

The designations employed and the presentation of material on this map do not imply the expression of any opinion whatsoever on the part of the World Health Organization concerning the legal status of any country, territory, city or area or its authorities, or concerning the delimitation of its frontiers or boundaries. Dotted lines represent approximate border lines for which there may not yet be full agreement.



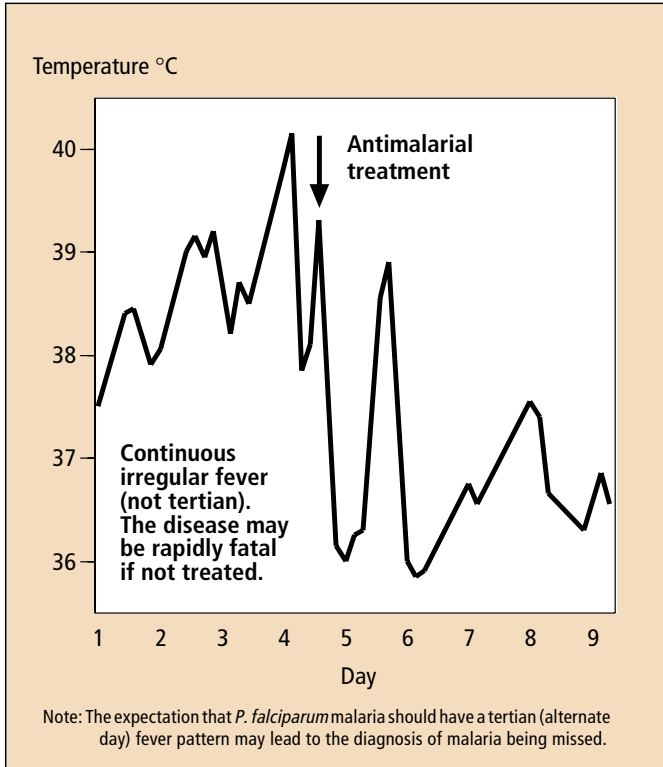


Fig. 2. Temperature chart characteristic of *P. falciparum* malaria

■ Severe falciparum malaria

A patient with severe falciparum malaria may present with confusion, or drowsiness with extreme weakness (prostration). In addition, the following may develop:

- Cerebral malaria, defined as unrousable coma not attributable to any other cause in a patient with falciparum malaria.
- Generalized convulsions.
- Severe normocytic anaemia.
- Hypoglycaemia.
- Metabolic acidosis with respiratory distress.
- Fluid and electrolyte disturbances.
- Acute renal failure.
- Acute pulmonary oedema and adult respiratory distress syndrome (ARDS).
- Circulatory collapse, shock, septicaemia (“algid malaria”).
- Abnormal bleeding.
- Jaundice.
- Haemoglobinuria.
- High fever.
- Hyperparasitaemia.

Important: These severe manifestations can occur singly or, more commonly, in combination in the same patient.

Who is at risk?

In high-transmission areas, the risk of severe falciparum malaria developing is greatest among young children, and visitors (of any age) from non-endemic areas. In non-transmission and low-transmission areas the risk is greatest among travellers returning, with undiagnosed malaria infection, from any area where *P. falciparum* transmission occurs.

General management

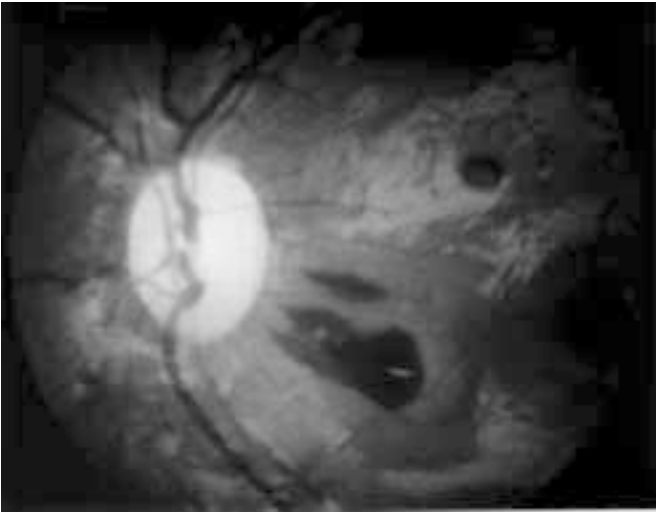
The following measures should be applied to all patients with clinically diagnosed or suspected severe malaria:

- Make a rapid clinical assessment with special attention to level of consciousness, blood pressure, rate and depth of respiration and pallor.
- Admit patient to an intensive care unit if this is available.
- If parasitological confirmation of malaria is not readily available, make a blood film and start treatment on the basis of the clinical presentation.
- Give antimalarial chemotherapy intravenously. If intravenous infusion is not possible, an appropriate drug may be given intramuscularly. Suppository formulations of artemisinin and its derivatives are becoming available and should be given if parenteral administration is not possible. Oral treatment should be substituted as soon as reliably possible (once patient can swallow and retain tablets).
- Calculate doses as mg/kg of body weight. Therefore, weigh the patient. This is particularly important for children.
- Do not confuse the doses of salt and base. Quinine doses are usually prescribed as the quinine salt (10 mg of quinine dihydrochloride salt = 8.3 mg of quinine base). Chloroquine and quinidine are commonly prescribed as base.
- Provide good nursing care. This is vital, especially if the patient is unconscious (see page 10).

- Pay careful attention to fluid balance, if fluids are being given intravenously, in order to avoid over- and under-hydration.
- Make a rapid initial check of the blood glucose level, and monitor frequently for hypoglycaemia. If this cannot be done, give glucose (see page 18).
- Examine the optic fundi by ophthalmoscope. This may help in differential diagnosis, and rarely will reveal papilloedema, which is a contraindication to performing a lumbar puncture. Retinal haemorrhages may be seen (Fig. 3), but these do not influence management.
- Make sure you look for other treatable causes of coma (see page 18). Meningitis should be excluded (by lumbar puncture) or covered by treatment (see page 22).
- Look for and manage any other complicating or associated infections.
- Record urine output and look for the appearance of black urine (haemoglobinuria) or oliguria which may indicate acute renal failure (see pages 10, 16 and 25).
- Monitor the core temperature (preferably rectal temperature), respiratory rate and depth, blood pressure, level of consciousness and other vital signs regularly. These observations will allow you to identify the late onset of important complications such as hypoglycaemia, metabolic acidosis, pulmonary oedema and shock.
- Reduce high body temperatures ($>39^{\circ}\text{C}$) by tepid sponging and fanning. Administer paracetamol as an antipyretic if necessary (see pages 10, 24 and 29).
- If the patient goes into shock, take blood cultures but start antibiotics without waiting for blood culture results.
- Monitor the therapeutic response, both clinical and parasitological, by regular observations and blood films.

- Carry out regular checks on packed cell volume (haematocrit) or haemoglobin concentration, glucose, urea or creatinine, and electrolytes.
- Avoid drugs that increase the risk of gastrointestinal bleeding (aspirin, corticosteroids).
- Remove an indwelling urinary catheter as soon as it is no longer necessary or if the patient becomes anuric.
- Clean insertion sites for intravenous lines at least twice daily with iodine and alcohol.

More sophisticated monitoring (e.g. measurement of arterial pH, blood gases, central venous pressure) may be useful if complications develop, and will depend on the local availability of equipment, experience and skills.



© K. Marsh

Fig. 3. Multiple retinal haemorrhages in cerebral malaria

Nursing care

Good nursing care of the patient with severe malaria is of vital importance.

- Ensure meticulous nursing care. This can be life-saving, especially for the unconscious patient. Maintain a clear airway. Nurse the patient in the lateral or semi-prone position to avoid aspiration of fluid. Insert a nasogastric tube and suck out the stomach contents to minimize the risk of aspiration pneumonia. Aspiration pneumonia is a potentially fatal complication that must be dealt with immediately (see inside back cover flap). Turn the patient every 2 hours. Do not allow the patient to lie in a wet bed. Pay particular attention to pressure points.
- Keep a careful record of fluid intake and output. If this is not possible, weigh the patient daily in order to calculate the approximate fluid balance.
- Note any appearance of black urine (haemoglobinuria).
- Check the speed of infusion of fluids frequently. Too fast or too slow an infusion can be dangerous.
- Monitor the temperature, pulse, respiration, blood pressure and level of consciousness (use the Glasgow coma scale for adults, or a paediatric scale for a child; see Annexes 2 and 3). These observations should be made at least every 4 hours until the patient is out of danger.
- Report changes in the level of consciousness, occurrence of convulsions or changes in behaviour of the patient immediately. All such changes suggest developments that require additional treatment.
- If the rectal temperature rises above 39 °C, remove the patient's clothes and start tepid sponging and fanning. Give paracetamol (the rectal route is usually best).

Specific antimalarial chemotherapy

The drugs appropriate for the treatment of severe falciparum malaria are given in Table 1 on the inside front cover flap. Information on the most commonly used drugs is given in Annex 1. Response should be monitored by frequent clinical examination including recording of fluid balance, temperature, pulse, respiratory rate and depth, level of consciousness, blood pressure, jugular venous pressure, and parasitaemia (in blood films) every 4–6 hours for the first 48 hours.

Chloroquine resistance is now virtually global and it is therefore advisable to treat all patients with severe malaria with quinine or, where appropriate, an artemisinin derivative.

Clinical features and management of complications in adults

In all cases of severe malaria, parenteral antimalarial chemotherapy should be started immediately. Any complications can then be dealt with as described below.

Cerebral malaria

Clinical features

The adult patient with cerebral malaria is comatose, the depth of consciousness being variable (for assessment of coma, see the Glasgow coma scale, Annex 2). If the cause is in doubt, test for other locally prevalent encephalopathies, e.g. bacterial, fungal or viral meningoencephalitides.

Asexual malaria parasites are usually demonstrable on a peripheral blood smear. Convulsions and retinal haemorrhages (Fig. 3) are common; papilloedema is rare. A variety of transient abnormalities of eye movement, especially disconjugate gaze, have been noted (Fig. 4). Fixed jaw closure and tooth grinding (bruxism) are common. Pouting may occur (Fig. 5) or a pout reflex may be elicited (by stroking the sides of the mouth). Mild neck stiffness occurs but neck rigidity and photophobia are absent. The commonest neurological picture in adults is one of a symmetrical upper motor neuron lesion.

Motor abnormalities such as decerebrate rigidity (Fig. 6) and decorticate rigidity (arms flexed and legs stretched), occur. Hepatosplenomegaly is common. The abdominal reflexes are invariably absent; this is a useful sign for distinguishing hysterical adult patients with fevers of other causes in whom these reflexes are usually brisk. The opening

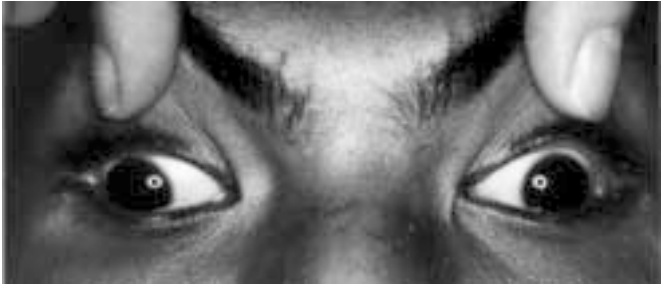pressure at lumbar puncture is usually normal in adults, but may be elevated; cerebrospinal fluid (CSF) is clear, with fewer than 10 white cells per μl ; the protein is often slightly raised, as is the CSF lactic acid concentration. A variety of nonspecific electroencephalographic abnormalities have been described; computerized tomography scans of the brain are usually normal.

(See pages 30–33 for a description of the clinical features of cerebral malaria in children.)

Management

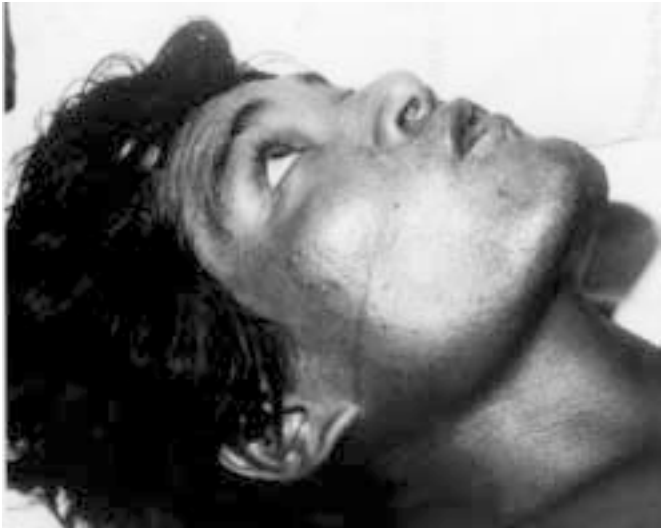- The comatose patient should be given meticulous nursing care (see page 10).
- Insert a urethral catheter using a sterile technique, unless the patient is anuric.
- Insert a nasogastric tube and aspirate stomach contents.
- Keep an accurate record of fluid intake and output.
- Monitor and record the level of consciousness (using the Glasgow coma scale, Annex 2), temperature, respiratory rate and depth, blood pressure and vital signs.
- Treat convulsions if and when they arise with diazepam or paraldehyde. A slow intravenous injection of diazepam (0.15 mg/kg of body weight, maximum 10 mg for adults) or intramuscular injection of paraldehyde (0.1 ml/kg of body weight), will usually control convulsions. Diazepam can also be given intrarectally (0.5–1.0 mg/kg of body weight) if injection is not possible.

Important: Paraldehyde should if possible be given from a sterile glass syringe. A disposable plastic syringe may be used provided that the injection is given immediately the paraldehyde is drawn up, and that the syringe is never reused.



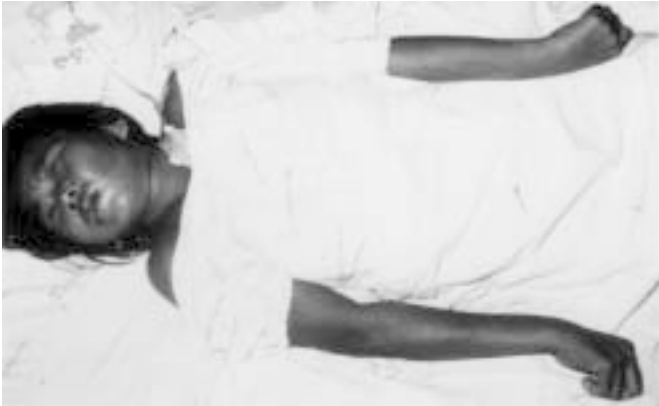© D. A. Warrell

Fig. 4. Disconjugate gaze in a patient with cerebral malaria: optic axes are not parallel in vertical and horizontal planes



© D. A. Warrell

Fig. 5. Pouting and sustained upward deviation of the eyes accompanied by laboured and noisy breathing in a patient with cerebral malaria complicated by hypoglycaemia



© D. A. Warrell

Fig. 6. **Decerebrate rigidity in a patient with cerebral malaria complicated by hypoglycaemia**

The following have been used or suggested for the treatment of cerebral malaria but are now considered either useless or dangerous, and should **not** be given:

- corticosteroids,
- other anti-inflammatory agents,
- other agents given for cerebral oedema (urea, invert sugar),
- low molecular weight dextran,
- epinephrine (adrenaline),
- heparin,
- epoprostenol (prostacyclin),
- ciclosporin (cyclosporin A),
- deferoxamine (desferrioxamine).

Anaemia

Clinical features

Anaemia is common in severe malaria and is often associated with secondary bacterial infection. Anaemia is a particularly important complication of malaria in young children and in pregnant women (see pages 34 and 44 respectively).

Management

- If the packed cell volume (haematocrit) falls below 20% or the haemoglobin concentration falls below 7 g/dl, give a transfusion of pathogen-free compatible fresh blood or packed cells. (Stored bank blood may be used if fresh blood is not available.) In areas where human immunodeficiency virus (HIV) is prevalent and facilities for screening are inadequate, the general condition of the patient (e.g. shock, cardiac failure) and the response to oxygen and colloid infusion should be the guiding principles rather than the haematocrit alone.
- Provided that the patient's renal function is adequate, give small intravenous doses of furosemide (frusemide), 20 mg, as necessary during the blood transfusion to avoid circulatory overload.
- Remember to include the volume of transfused cells or blood in calculations of fluid balance.

Renal failure

Clinical features

Renal failure as a complication of malaria is virtually confined to adults. There is a rise in serum creatinine and blood urea, oliguria and eventually anuria due to acute tubular

necrosis. Although usually oliguric, renal failure may occasionally be polyuric. The mechanism of acute tubular necrosis in malaria is not fully understood.

Acute renal failure is usually reversible.

Management

- Exclude dehydration (hypovolaemia) by clinical examination, including measurement of jugular or central venous pressure (Annex 6), and blood pressure drop between the patient lying supine and when propped up to 45°.
- Carefully infuse isotonic saline, monitoring the jugular venous pressure clinically with the patient propped up to 45° (Annex 6).
- Peritoneal dialysis or haemodialysis is indicated if the patient remains oliguric after adequate rehydration and the blood urea and creatinine rise progressively.
- Peritoneal dialysis should not be undertaken lightly. If possible, refer the patient to a dialysis unit or centre.

Hypoglycaemia

Clinical features

Hypoglycaemia is an important manifestation of falciparum malaria. It occurs in three different groups of patients which may overlap:

- patients with severe disease, especially young children (see page 38);
- patients treated with quinine or quinidine, as a result of a quinine-induced hyperinsulinaemia;
- pregnant women, either on admission or following quinine treatment (see page 43).

In conscious patients, hypoglycaemia may present with classical symptoms of anxiety, sweating, dilatation of the pupils, breathlessness, oliguria, a feeling of coldness, tachycardia and light-headedness. This clinical picture may develop into deteriorating consciousness, generalized convulsions, extensor posturing, shock and coma.

The diagnosis is easily overlooked because all these clinical features also occur in severe malaria itself. A deterioration in the level of consciousness may be the only sign. If possible, confirm by biochemical testing, especially in the high-risk groups mentioned above.

Management

- If hypoglycaemia is detected by blood testing or suspected on clinical grounds, give 50% dextrose, 50 ml (1.0 ml/kg of body weight for children). This should be diluted in an approximately equal volume of any infusion fluid and infused over a period of about 5 minutes.
- Follow with a continuous intravenous infusion of 5% or 10% dextrose.
- Continue to monitor blood glucose levels (using a "stix" method if available, or clinically and biochemically if not) in order to regulate the dextrose infusion. Remember that hypoglycaemia may recur even after treatment with intravenous dextrose.

Fluid and electrolyte disturbances

Clinical features

Patients with severe falciparum malaria often show the following on admission: clinical evidence of *hypovolaemia* – low jugular venous pressure, postural hypotension, and oliguria with high urine specific gravity; and clinical signs

of *dehydration* – dry mucous membranes and decreased skin turgor.

Acidotic breathing – hyperventilation, deep breathing – may develop in severely ill patients who are shocked, hypoglycaemic, hyperparasitaemic or in renal failure. This is usually due to lactic acidosis, and lactic acid concentrations in both blood and CSF are raised. Perfusion is improved by correcting hypovolaemia.

Management

- Look for evidence of dehydration and hypovolaemia:
 - dry mucous membranes,
 - reduced skin turgor,
 - relatively cool extremities,
 - postural drop in blood pressure (as the patient is propped up from lying flat to 45°),
 - reduced peripheral venous filling, or slow capillary refill time
 - low jugular venous pressure,
 - reduced urine output,
 - high urine specific gravity,
 - urine sodium concentration less than 20 mmol/l.
- If there is evidence of dehydration, give only isotonic fluid (0.9% saline) by intravenous infusion, but avoid circulatory overload as it may rapidly precipitate fatal pulmonary oedema.
- Monitor blood pressure, urine volume (every hour) and jugular venous pressure (Annex 6).
- Improve oxygenation by
 - clearing airway,
 - increasing concentration of inspired oxygen,
 - supporting ventilation artificially, if necessary.

Pulmonary oedema

Clinical features

Pulmonary oedema is a grave complication of severe malaria, with a high mortality (over 80%). It may appear several days after chemotherapy has been started and at a time when the patient's general condition is improving and the peripheral parasitaemia is diminishing. In most cases there are features of adult respiratory distress syndrome (ARDS), implying increased pulmonary capillary permeability. Pulmonary oedema may also arise iatrogenically from fluid overload. The two conditions are difficult to distinguish clinically and may coexist in the same patient. Pulmonary oedema is often associated with other complications of malaria and may also occur in vivax malaria. The first indication of impending pulmonary oedema is an increase in the respiratory rate, which precedes the development of other chest signs (Fig. 7). The arterial pO_2 is reduced.

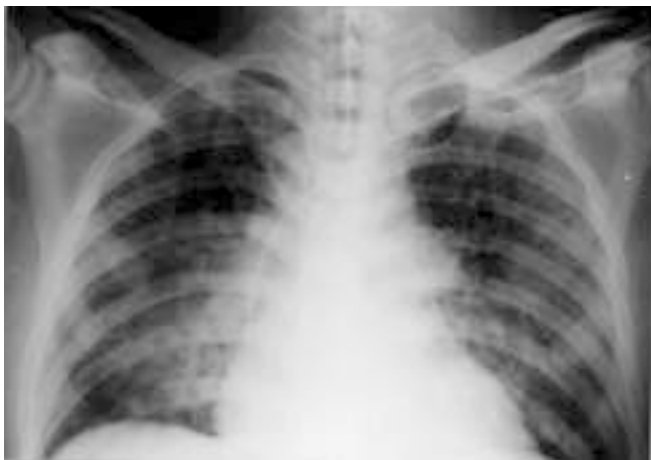

Fig. 7. Radiographic appearance of acute pulmonary oedema, resembling adult respiratory distress syndrome, in a patient with cerebral malaria

Hypoxia may cause convulsions and deterioration in the level of consciousness and the patient may die within a few hours.

Management

- Keep the patient upright; raise the head of the bed or lower the foot of the bed.
- Give a high concentration of oxygen by any convenient method available, including mechanical ventilation.
- Give the patient a diuretic, such as furosemide (frusemide), 40 mg, by intravenous injection. If there is no response, increase the dose progressively to a maximum of 200 mg.
- In well-equipped intensive care units, mechanical ventilation with positive end-expiratory pressure (PEEP), a wide range of vasoactive drugs and haemodynamic monitoring will be available.

If there is pulmonary oedema due to overhydration in addition to the above:

- Stop all intravenous fluids.
- Use haemofiltration immediately, if available.
- If there is no improvement, withdraw 250 ml of blood by venesection into a blood transfusion donor bag so that it can be given back to the patient later.

Circulatory collapse (“algid malaria”)

Clinical features

Some patients are admitted in a state of collapse, with a systolic blood pressure less than 80 mmHg (10.7 kPa) in the supine position (less than 50 mmHg (6.67 kPa) in children); a cold, clammy, cyanotic skin; constricted peripheral veins; rapid feeble pulse. In some countries this clinical picture is often associated with a complicating Gram-negative septicaemia.

Circulatory collapse is also seen in patients with pulmonary oedema or metabolic acidosis, and following massive gastrointestinal haemorrhage or ruptured spleen. Dehydration with hypovolaemia may also contribute to hypotension.

Possible sites of associated infection should be sought, e.g. lung, urinary tract (especially if there is an indwelling catheter), meninges (meningitis), intravenous injection sites, intravenous lines.

Management

- Correct hypovolaemia with an appropriate plasma expander (fresh blood, plasma, dextran 70 or polyglycans). If these are not available give isotonic saline.
- Take a blood culture and start the patient on broad-spectrum antibiotics immediately, e.g. a penicillin or cephalosporin combined with a single dose of gentamicin.
- Once the results of blood culture and sensitivity testing are available, give the appropriate antibiotic.
- Monitor central venous pressure (Annex 6).

Abnormal bleeding and disseminated intravascular coagulation

Clinical features

Bleeding gums, epistaxis, petechiae and subconjunctival haemorrhages may occur (Fig. 8). Disseminated intravascular coagulation, complicated by clinically significant bleeding, e.g. haematemesis or melaena, occurs in fewer than 10% of patients. It is more common in non-immune patients with imported malaria in the temperate zone.

Thrombocytopenia is very common in falciparum malaria, usually without other coagulation abnormalities. In most cases it is unaccompanied by bleeding. The platelet count usually returns to normal after successful treatment of the malaria.



© D. A. Warrell

Fig. 8. A patient with profound anaemia, cerebral malaria, disseminated intravascular coagulation and spontaneous bleeding from the gums

Management

- Transfuse fresh blood, clotting factors or platelets as required.
- Give vitamin K, 10 mg, by slow intravenous injection.

High fever

Clinical features

High fever (39–40 °C) is especially common in children and may contribute to convulsions and altered consciousness. There is evidence that high body temperature in pregnant women contributes to fetal distress (see page 42).

Sustained very high body temperatures (42 °C and above), which may cause permanent severe neurological sequelae in patients with heat-stroke, are rarely seen in malaria.

Management

- Monitor rectal temperature frequently.
- If rectal temperature is above 39 °C, remove the patient's clothes, apply tepid sponging and fanning, and give paracetamol, 15 mg/kg of body weight, by mouth, suppository or nasogastric tube.

Hyperparasitaemia

Clinical features

In general, and especially in non-immune subjects, high parasite densities (above 5%) and peripheral schizontaemia are associated with severe disease; however, in highly endemic malarious areas, partially immune children can tolerate surprisingly high densities (20–30%) often without clinical symptoms.

Management

- Antimalarial therapy should be initiated immediately, preferably by a parenteral route (see Table 1, inside front cover flap) even if the patient can take medication by mouth.
- If parasitaemia exceeds 10% in severely ill patients, especially those deteriorating after optimal chemotherapy, exchange transfusion with screened blood should be considered where facilities are available.

Malarial haemoglobinuria

Clinical features

Patients with glucose-6-phosphate dehydrogenase (G6PD) deficiency may develop intravascular haemolysis and haemoglobinuria precipitated by primaquine and other oxidant drugs, even in the absence of malaria. Haemoglobinuria associated with malaria (“blackwater fever”) is uncommon and malarial haemoglobinuria usually presents in adults as severe disease with anaemia and renal failure.

Management

- Continue appropriate antimalarial treatment (see Table 1, inside front cover flap) if parasitaemia is present.
- Transfuse screened fresh blood if needed.
- Monitor central venous pressure to avoid fluid overload and hypovolaemia.
- If oliguria develops and blood urea and serum creatinine levels rise (i.e. if acute renal failure develops), peritoneal dialysis or haemodialysis may be required. If possible, refer the patient to a dialysis unit or centre.

Special clinical features of severe malaria and management of common complications in children

Severe malaria

Clinical features

Many of the clinical features of severe malaria described on pages 12–25 also occur in children. Only certain additional points will be highlighted here. The commonest and most important complications of *P. falciparum* infection in children are **cerebral malaria**, **severe anaemia**, **respiratory distress** (acidosis – see page 19) and **hypoglycaemia**.

The differences between severe malaria in adults and in children are given in Table 2.

Initial assessment

Key aspects of the initial assessment of children with severe malaria are:

- level of consciousness (coma scale for children, Annex 3),
- rate and depth of respiration,
- presence of anaemia,
- pulse rate and blood pressure,
- state of hydration,
- temperature.

Immediate tests must include:

- thick and thin blood films,
- packed cell volume (haematocrit),
- finger-prick blood glucose, lumbar puncture.

There is some disagreement about whether a lumbar puncture should be done routinely in a child with suspected cerebral malaria. Only a lumbar puncture can rule out bacterial meningitis. If it is decided to delay lumbar puncture, antibiotics must be given to cover the possibility of bacterial meningitis.

Nursing care

Nursing must include all the well-established principles of the care of the unconscious child; including frequent turning (every 2 hours) and careful attention to airway, eyes, mucosae, skin and fluid requirements. The child should be nursed in the lateral or semi-prone position.

Emergency measures

- Insert nasogastric tube to minimize risk of aspiration pneumonia.
- Correct hypoglycaemia.
- Restore circulating volume.
- Treat anaemia.

Management

The management of severe malaria in children is generally similar to that in adults (see page 7). Some specific aspects are re-emphasized here.

- The parents or other relatives should be questioned about: (i) history of residence or travel; (ii) previous treatment with antimalarials or other drugs; (iii) recent fluid intake and urine output; and (iv) recent or past history of convulsions.
- If the child is unconscious, insert a nasogastric tube to minimize the risk of aspiration pneumonia. Evacuate the stomach contents (this may reveal evidence of noxious substances given to the child).

- If parasitological confirmation is likely to take more than 1 hour, treatment should be started before the diagnosis is confirmed.
- Treat convulsions with intravenous diazepam, 0.3 mg/kg of body weight as a slow bolus (“push”) over 2 minutes or 0.5 mg/kg of body weight intrarectally. Alternatively, paraldehyde 0.1 ml/kg of body weight may be given by deep intramuscular injection or 0.4 ml/kg of body weight intrarectally using a sterile glass syringe. (A disposable plastic syringe may be used provided that the injection is given immediately the paraldehyde is drawn up and that the syringe is never reused.)
- In general, children with metabolic acidosis who have not previously received parenteral fluids are dehydrated and should be managed accordingly (see page 19).
- In any child with convulsions, hyperpyrexia and hypoglycaemia should be excluded. Whereas prophylactic anticonvulsants have been recommended in the past, recent evidence suggests that 20 mg/kg of phenobarbital may be harmful.
- Paracetamol, 15 mg/kg of body weight 4-hourly, may also be given orally or rectally as an antipyretic.
- Use tepid sponging and fanning to try to keep the rectal temperature below 39°C. Relatives are usually happy to do this when instructed.
- Avoid harmful ancillary drugs (see page 15).

Table 2 Differences between severe malaria in adults and in children^a

Sign or symptom	Adults	Children
History of cough	Uncommon	Common
Convulsions	Common	Very common
Duration of illness	5–7 days	1–2 days
Resolution of coma	2–4 days	1–2 days
Neurological sequelae	<5%	>10%
Jaundice	Common	Uncommon
Pretreatment hypoglycaemia	Uncommon	Common
Pulmonary oedema	Uncommon	Rare
Renal failure	Common	Uncommon
CSF opening pressure	Usually normal	Usually raised
Respiratory distress (acidosis)	Sometimes	Common
Bleeding/clotting disturbances	Up to 10%	Rare
Abnormality of brain stem reflexes (e.g. oculovestibular, oculocervical).	Rare	More common

^aDerived from studies in south-east Asian adults and children, and African children.

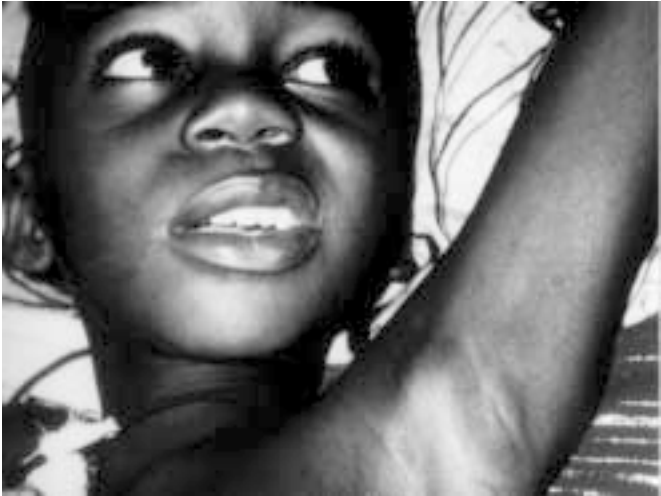Cerebral malaria

Clinical features

- The earliest symptom of cerebral malaria in children is usually fever (37.5–41°C), followed by failure to eat or drink. Vomiting and cough are common; diarrhoea is unusual.

- The history of symptoms preceding coma may be very brief – commonly one or two days.
- A child who loses consciousness after a febrile convulsion should not be classified as having cerebral malaria unless coma persists for more than 1 hour after the convulsion. Antimalarial treatment must not be delayed.
- The depth of coma may be assessed according to the coma scale for children (Annex 3) by observing the response to standard vocal or painful stimuli (rub knuckles on child's sternum; if there is no response, apply firm pressure on thumbnail bed with horizontal pencil).
- Always exclude or treat hypoglycaemia (see page 38).
- Convulsions are common before or after the onset of coma. They are significantly associated with morbidity and sequelae. They may present in a very subtle way – important signs include intermittent nystagmus, salivation, minor twitching of a single digit or a corner of the mouth (Fig. 9) and an irregular breathing pattern.
- Deep breathing with a clear chest is a sensitive and specific sign for the presence of metabolic acidosis.
- A few children have cold, clammy skin, with a core-to-skin temperature difference of 10 °C. Some of these patients are in a state of shock with a systolic blood pressure below 50 mmHg (6.67 kPa).
- In children with profound coma, corneal reflexes and “doll's eye” movements may be abnormal.
- In some children, extreme opisthotonos is seen (Fig. 10), which may lead to a mistaken diagnosis of tetanus or meningitis.
- CSF opening pressure is usually raised.

- Leukocytosis is not unusual in severe disease and does not necessarily imply an associated bacterial infection. (This is also true in adults.)
- About 10% of children who survive cerebral malaria have neurological sequelae which persist into the convalescent period. Sequelae may take the form of cerebellar ataxia, hemiparesis, speech disorders, cortical blindness, behavioural disturbances, hypotonia or generalized spasticity.



© J. Crawley

Fig. 9. Subtle convulsion in a child with cerebral malaria. Note deviation of the eyes to the left (there was nystagmus), raising of the corner of the mouth and stereotyped raising of the left arm

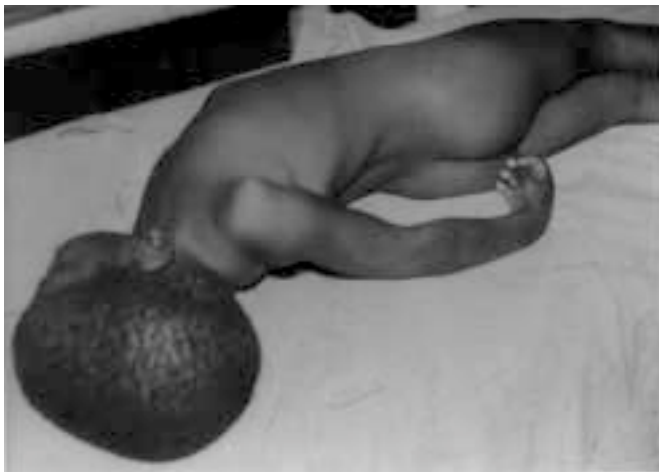

Fig. 10. **Opisthotonos** in an unrousably comatose child with cerebral malaria. The cerebrospinal fluid cell count was normal

Management

- The management of severe malaria in children is the same as in adults (page 13), including careful nursing and monitoring of the unconscious patient.
- The child with cerebral malaria may also have anaemia, respiratory distress (acidosis) and hypoglycaemia and has to be managed accordingly (see pages 34–39).

Anaemia

Clinical features

In African children anaemia is a common presenting feature (Fig. 11). Asexual parasitaemia is sometimes low but there is abundant malarial pigment in monocytes and other phagocytic cells, reflecting recent or resolving infection.

The rate of development and degree of anaemia depend on the severity and duration of parasitaemia. In some children, repeated untreated episodes of otherwise uncomplicated malaria may lead to normochromic anaemia in which dyserythropoietic changes in the bone marrow are prominent. Parasitaemia is often scanty, although numerous pigmented monocytes can be seen in the peripheral blood.



© D. A. Warrell

Fig. 11. Profound anaemia (haemoglobin 1.2 g/dl) in a child who had suffered repeated attacks of malaria and, on this occasion, had a high *P. falciparum* parasitaemia

Children with hyperparasitaemia may develop severe anaemia rapidly. In these cases, acute destruction of parasitized red cells is responsible.

Children with severe anaemia may present with tachycardia and dyspnoea. Anaemia may contribute to *cerebral signs* – confusion, restlessness, coma and retinal haemorrhages; *signs of acidosis* – deep, sometimes laboured, breathing; and rarely, *cardiopulmonary signs* – gallop rhythm, cardiac failure, hepatomegaly and pulmonary oedema.

Management

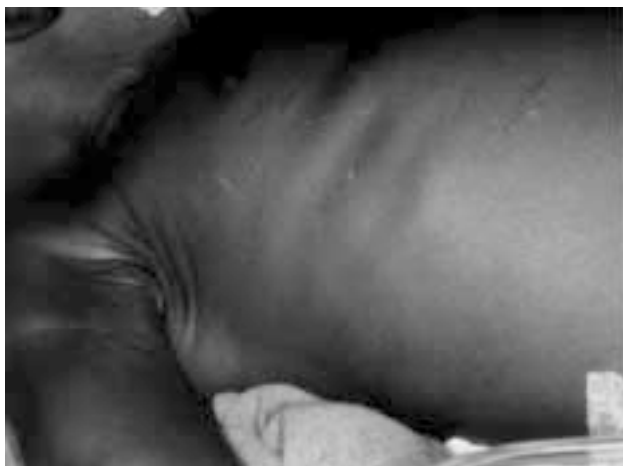- The need for blood transfusion must be assessed with great care in each individual child. Not only packed cell volume (haematocrit) or haemoglobin concentration, but also the density of parasitaemia and the clinical condition of the patient must be taken into account.
- In general, a packed cell volume (haematocrit) of 12% or less, or a haemoglobin concentration of 4 g/dl or less, is an indication for blood transfusion, whatever the clinical condition of the child. In some children, an initial transfusion is required with the utmost urgency (10 ml of packed cells or 20 ml of whole blood per kg of body weight).
- In children with less severe anaemia (i.e. packed cell volume 13–18%, Hb 4–6 g/dl), transfusion should be considered for high-risk patients with any one of the following clinical features: (i) respiratory distress (acidosis); (ii) impaired consciousness; (iii) hyperparasitaemia (>20%).
- Anaemic children with respiratory distress are, contrary to usual belief, rarely in congestive cardiac failure. More commonly their dyspnoea is due to acidosis, resulting from tissue hypoxia, often associated with hypovolaemia. The sicker the child the more rapidly the transfusion needs to be given.

- If HIV-screened blood is not available, fresh blood from an elderly relative is preferable for transfusion as the prevalence of HIV infection is lower in this age group.
- A diuretic is usually not indicated as many of these children are hypovolaemic. However, if there is fluid overload, furosemide (frusemide), 1–2 mg/kg of body weight up to a maximum of 20 mg, may be given intravenously.

Respiratory distress (acidosis)

Clinical features

Deep breathing, with indrawing (recession) of the bony structures of the lower chest wall, in the absence of localizing chest signs suggests metabolic acidosis – frequently lactic acidosis. Indrawing (recession) of the intercostal



© D. A. Warrell

Fig. 12. Deep acidotic breathing with intercostal recession in a child with severe falciparum malaria

spaces (Fig. 12) is a less useful sign. Respiratory distress (acidosis) commonly accompanies cerebral malaria or anaemia but it may develop in a child without impaired consciousness. In either case it is associated with an increased risk of death. A systolic blood pressure below 50 mmHg (6.67 kPa) indicates a state of shock.

Management

- Correct any reversible cause of acidosis, in particular dehydration and severe anaemia. Intravenous infusion is best, using the most accessible site, including the femoral vein (Annex 4). If this is impossible, give an intra-osseous infusion (Annex 5). Take care not to give excessive fluid, as this may precipitate pulmonary oedema.
- Because convulsions may contribute to lactic acidosis, prevention of further seizures may be beneficial.
- If the haematocrit is more than 15% or the haemoglobin concentration is more than 5 g/dl, give 20 ml/kg of body weight of isotonic saline, by intravenous infusion over 30 minutes.
- If the haematocrit is less than 15% or the haemoglobin concentration is less than 5 g/dl in a child with signs of metabolic acidosis, give screened whole blood, 10 ml/kg of body weight over 30 minutes and a further 10 ml/kg of body weight over 1–2 hours without diuretics.
- Monitor response by continuous clinical observation supported by repeated measurement of acid–base status, haematocrit or haemoglobin concentration, and glucose, urea and electrolyte levels.

Hypoglycaemia

Clinical features

Hypoglycaemia is particularly common in children under 3 years and in those with convulsions or hyperparasitaemia or in a profound coma. It is easily overlooked clinically because the manifestations may be similar to those of cerebral malaria (see also pages 30–33).

Management

- Unconscious children should be given dextrose regularly to prevent starvation hypoglycaemia. It is most conveniently provided as 5% dextrose in saline infusion, but if this would be likely to lead to fluid overload, smaller volumes of more concentrated dextrose may be given at regular intervals.
- If hypoglycaemia occurs, give intravenous 50% dextrose in a dose of 1.0 ml/kg of body weight (0.5 g/kg) diluted in approximately the same volume of IV fluid slowly over several minutes. If only 25% or 10% dextrose is available, give appropriately more to provide the same amount of dextrose (0.5 g/kg). This should be followed by a slow intravenous infusion of 5% or 10% dextrose to prevent recurrence of hypoglycaemia. If the intravenous route is impossible, intra-osseous access (Annex 5) should be tried. If this fails, 1 ml/kg of body weight of 50% dextrose – or of any sugary solution – may be given through a nasogastric tube.
- The duration and amount of dextrose infusion will be dictated by the results of blood glucose monitoring (which should be done in blood taken from the arm opposite to that receiving the infusion), using a “stix” method. (N.B. For economy, a stix can be divided longitudinally – but not if it is to be read in a reflectance meter.)

- Monitoring of blood glucose levels should continue even after successful correction as hypoglycaemia may recur.

Dehydration

Clinical features

The best evidence of mild to moderate dehydration in children is decreased peripheral perfusion, decreased skin turgor, raised blood urea > 6.5 mmol/l (> 36.0 mg of urea/dl) and increased thirst.

In children presenting with oliguria and dehydration, examination of urine usually reveals a high specific gravity, low urinary sodium and a normal urinary sediment, indicating simple dehydration rather than renal failure (which is rare in children).

Management

- Rehydrate quickly with isotonic saline. Frequently examine the jugular venous pressure, blood pressure, chest, heart and liver size, to make sure the patient is not being given too much fluid.
- Where facilities for monitoring and maintenance of adequate sterility exist, fluid balance may be adjusted in accordance with direct measurement of the central venous pressure through a central venous catheter.
- If, after careful rehydration, urine output in the first 8 hours is less than 4 ml/kg of body weight, furosemide (frusemide) can be given intravenously, initially at 2 mg/kg of body weight, then doubled at hourly intervals to a maximum of 8 mg/kg of body weight (given over 15 minutes).

Antimalarial drugs

(see Table 1 inside front cover flap and Annex 1)

Ideally, antimalarial drugs should be given initially by intravenous infusion; this should be replaced by oral administration as soon as possible.

Weigh the patient, and calculate the dose of antimalarials according to body weight (mg/kg of body weight) (Table 1).

If intravenous infusion is not possible, chloroquine and quinine may be given by intramuscular injection into the anterior thigh (not into the buttock, where absorption is slow and uncertain and the sciatic nerve is at risk). Chloroquine – but not quinine – may also be given by subcutaneous injection.

Artesunate can be given intravenously by bolus (“push”) injection, intramuscularly or by suppository. Artemisinin is also available as a suppository. Artemether can only be administered intramuscularly.

Do not attempt to give oral medication to unconscious children; if parenteral injection is not possible and referral is likely to be delayed, consider using artesunate, or artemisinin, suppositories. Crushed antimalarials may be given by nasogastric tube. However, nasogastric administration may cause vomiting and produce inadequate drug levels in the blood.

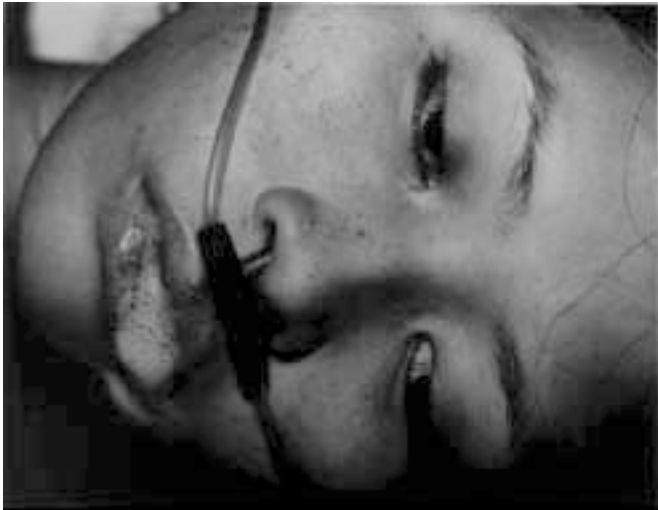Special clinical features and management of severe malaria in pregnancy

Severe malaria

Clinical features

Pregnant women with malaria must be treated promptly because the disease is more severe, is associated with high parasitaemia and is dangerous for mother and fetus.

The clinical manifestations of malaria in pregnancy may vary greatly according to their level of immunity.



© S. Loareesuwan

Fig. 13. Acute pulmonary oedema developing immediately after delivery in a patient

Non-immune pregnant women are susceptible to all the complications described on pages 12–25. They have an increased risk of abortion (in severe malaria), stillbirth, premature delivery and low infant birth weight. They are more likely to develop cerebral and other forms of severe malaria, and to suffer a high mortality (2–10 times higher than non-pregnant patients). They are particularly susceptible to hypoglycaemia and acute pulmonary oedema (Fig. 13).

Partially immune pregnant women, especially primigravidae, are susceptible to severe anaemia but the other manifestations of severe malaria are unusual. They are particularly at risk because their malarial infection is often asymptomatic and may be overlooked because peripheral blood films may be negative. Other signs suggestive of severe disease in these women, such as unconsciousness or convulsions, are more likely to be due to other causes, such as eclampsia or meningitis.

Falciparum malaria commonly induces uterine contractions and gives rise to premature labour. The frequency and intensity of contractions appear to be related to the height of the fever. Fetal distress is common, but frequently not diagnosed. The prognosis for the fetus is poor in severe disease. The risk of abortion and low infant birth weight is increased, especially in first pregnancies.

Associated infections occur; pneumonia and urinary tract infections are common.

Management

- Pregnant women with severe malaria should be transferred to intensive care if possible.
- Malaria may lead to threatened premature labour or may result in established labour, despite prompt antimalarial treatment.

- Once labour has started, fetal or maternal distress may indicate the need to intervene, and the second stage may need to be shortened by the use of forceps, vacuum extraction or caesarean section.
- Women with severe anaemia in endemic areas, especially primigravidae, should be given full antimalarial treatment even if peripheral blood films are negative and there are no other features to suggest malaria.

Hypoglycaemia

Clinical features (see page 17)

Hypoglycaemia may be present in pregnant women on admission, or may occur after quinine infusion. It is commonly asymptomatic, although it may be associated with fetal bradycardia and other signs of fetal distress. In the most severely ill patients, it is associated with lactic acidosis and high mortality.

In patients who have been given quinine, abnormal behaviour, sweating and sudden loss of consciousness are the usual manifestations.

Management

- Treat as described on page 18. If the diagnosis is in doubt, a therapeutic trial with 50% dextrose (20–50 ml intravenously) given over 5–10 minutes should be used.
- Recurrent severe hypoglycaemia may be a problem in pregnant women with hypoglycaemia.
- If injectable dextrose is not available, dextrose or sugary solution can be given to an unconscious patient through a nasogastric tube.

Pulmonary oedema

Clinical features

Pulmonary oedema may be present in pregnant women on admission, may develop suddenly and unexpectedly several days after admission, or may occur immediately after childbirth (Fig. 13) (see also page 20).

Management

Treat as described on page 21.

Anaemia

Clinical features (see page 16)

Maternal anaemia is associated with maternal and perinatal morbidity and mortality and an increased risk of fatal postpartum haemorrhage. The malarial anaemia may be complicated by iron and/or folic acid deficiency anaemia.

Women who go into labour when severely anaemic or fluid-overloaded may develop pulmonary oedema after separation of the placenta.

Management

- Women with a packed cell volume (haematocrit) lower than 20% or a haemoglobin concentration less than 7 g/dl should receive a slow transfusion of screened packed cells over 6 hours (with the precautions mentioned on page 16) and furosemide (frusemide) 20 mg intravenously.
- Folic acid and iron supplements may be required.

Antimalarial drugs

Quinine, in the doses advocated for the treatment of life-threatening malaria, is safe in pregnancy. It has been shown that the initial intravenous infusion of quinine in women who are more than 30 weeks pregnant is not associated with uterine stimulation or fetal distress. Its major adverse effect is hypoglycaemia. Artesunate and artemether have been used safely and successfully in pregnancy in a small number of cases. In exceptional circumstances, when the other anti-malarial drugs are not available, sulfadoxine–pyrimethamine injectable formulations can be used in severe disease. The use of chloroquine is now severely limited by widespread parasite resistance. No teratogenic or other severe adverse effects on the fetus have been reported despite extensive use of chloroquine in the past.

Semi-immune women with severe anaemia and no other features of severe disease should be treated with an effective oral preparation, the choice of drug depending on safety and local patterns of drug resistance. Sulfadoxine–pyrimethamine is a suitable choice for many areas.

HIV seropositive women have an increased risk of *P. falciparum* malaria early in pregnancy. It seems that any immunoprotection gained from multi-pregnancies is lost because multiparous pregnant women who are HIV-positive are also afflicted with malaria. The protection from two doses of sulfadoxine–pyrimethamine (at first visit and again in the first part of the last trimester) is not adequate in HIV-seropositive women. In these cases three doses are preferred: in the first trimester, at 28 weeks and again at 32–34 weeks. It would be a reasonable policy to give this 3-dose regimen to all pregnant women in a population if the HIV-seropositivity rate in pregnancy is over 10%.

■ **Diagnosis of malaria**

Clinical diagnosis

The most important element in the clinical diagnosis of malaria, in both endemic and non-endemic areas, is to have a high index of suspicion.

Because the distribution of malaria is patchy, even in countries where it is known to be prevalent, a geographical and travel history indicative of exposure is important. In addition, the possibility of induced malaria (through transfusion or use of contaminated needles) must not be overlooked.

Severe malaria can mimic many other diseases that are also common in malarious countries. The most important of these are all types of meningitis, typhoid fever and septicaemia. Other differential diagnoses include influenza, dengue and other arbovirus infections, hepatitis, leptospirosis, the relapsing fevers, haemorrhagic fevers, scrub typhus, all types of viral encephalitis (including rabies), gastroenteritis and, in Africa, trypanosomiasis.

In pregnant women, malaria must be distinguished from sepsis arising in the uterus, urinary tract or breast.

In children, convulsions due to malaria must be differentiated from febrile convulsions. In the latter, coma usually does not last for more than half an hour, although some children do not regain full consciousness until 30–60 minutes after the ictal phase.

Parasitological diagnosis

In the majority of cases, examination of thick and thin films of the peripheral blood will reveal malaria parasites. Thick films are more useful than thin films in the detection of a

low-density malaria parasitaemia (Figs 14 and 15). Facilities and equipment for microscopic examination of blood films can be easily set up in the side-room of a clinic or ward, and films can be read by trained personnel on site. This reduces the delay that commonly occurs when samples must be sent to a distant laboratory.

In general, the greater the parasite density in the peripheral blood, the greater the likelihood that severe disease is present or will develop. This is especially true among “non-immune” people. Remember, however, that some individuals develop severe and even fatal malaria with a very low peripheral parasitaemia. Very rarely the blood film may actually be negative in a patient who is then proved at autopsy to have intense tissue sequestration of parasites.

There may be a marked difference between the number of parasitized cells in the peripheral blood and the number sequestered; moreover, rapid changes may be expected in synchronous infections. Frequent monitoring of the parasitaemia (every 4–6 hours) is very important for the first 2–3 days of treatment. The prognostic value of the parasite count may be improved considerably by assessing the stage of parasite development in the peripheral blood film. At any parasitaemia, prognosis worsens if there is a predominance of more mature parasite stages. In general, if more than 50% of the peripheral blood parasites are at the tiny ring stage (diameter of the nucleus <50% of the diameter of the rim of cytoplasm), the prognosis is relatively good. If more than 20% of parasites contain visible pigment (i.e. mature trophozoites or schizonts), the prognosis is relatively bad.

The presence of malaria pigment in polymorphonuclear leukocytes (neutrophils) is a useful indication of the diagnosis of malaria, especially in anaemic children and in

patients with severe malaria associated with absent or low parasitaemia. Assessment of peripheral blood polymorphonuclear leukocyte pigment is an extremely rapid and relatively accurate prognostic index whereby if more than 5% of the polymorphonuclear leukocytes contain visible pigment the prognosis worsens.

Several new but more costly rapid diagnostic tests are now available. However, these do not replace microscopy as the standard method for the diagnosis of severe malaria and the monitoring of its management as they do not provide the valuable observations mentioned above.

Haematological and biochemical findings

Anaemia is normocytic and may be “severe” (haemoglobin < 4 g/dl). Thrombocytopenia (< 100 000 platelets/ μ l) is usually present, and peripheral leukocytosis is found in patients with the most severe disease. Elevation of serum creatinine, bilirubin and enzymes, e.g. aminotransferases and 5'-nucleotidase, may be found. Levels of liver enzymes are much lower than in acute viral hepatitis. Severely ill patients are commonly acidotic, with low capillary plasma pH and bicarbonate concentrations. Fluid and electrolyte disturbances (sodium, potassium, chloride, calcium and phosphate) are variable. Concentrations of lactic acid in the blood and cerebrospinal fluid are often high in both adults and children, in proportion to the severity of the disease.

Prognostic indicators

The major indicators of a poor prognosis in children and adults with severe malaria are listed below.

Clinical indicators

Age under 3 years

Deep coma

Witnessed or reported convulsions

Absent corneal reflexes

Decerebrate/decorticate rigidity (Fig. 6) or opisthotonos (Fig. 10)

Clinical signs of organ dysfunction (e.g. renal failure, pulmonary oedema)

Respiratory distress (acidosis)

Circulatory collapse

Papilloedema and/or retinal oedema

Laboratory indicators

Hyperparasitaemia ($>250\,000/\mu\text{l}$ or $>5\%$) (see page 25)

Peripheral schizontaemia (Figs 14 and 15)

Peripheral blood polymorphonuclear leukocytosis ($>12\,000/\mu\text{l}$)

Mature pigmented parasites ($>20\%$ of parasites)

Peripheral blood polymorphonuclear leukocytes with visible malaria pigment ($>5\%$)

Packed cell volume less than 15%

Haemoglobin concentration less than 5 g/dl

Blood glucose less than 2.2 mmol/l (<40 mg/dl)

Blood urea more than 60 mg/dl

Serum creatinine more than $265\ \mu\text{mol/l}$ (>3.0 mg/dl)

High CSF lactic acid (>6 mmol/l) and low CSF glucose







Raised venous lactic acid (>5 mmol/l)

More than 3-fold elevation of serum enzymes (aminotransferases)

Increased plasma 5'-nucleotidase

Low antithrombin III levels

Very high plasma concentrations of tumour necrosis factor (TNF)

Stage of parasite in peripheral blood		Species
Trophozoites	Schüffner	Gametocyte
 <p>Size: small to medium; number: often numerous; shape: ring and comma forms common; chromatin: often two dots; cytoplasm: regular, fine to feebly mature forms; sometimes present in severe malaria; compact with pigment as few coarse grains or a mass.</p>	 <p>Usually associated with many young ring forms. Size: small, compact; number: few, uncommon, usually in severe malaria; mature forms: 12-30 or more merozoites in compact cluster; pigment: single dark mass.</p>	 <p>Immature pointed-end forms uncommon. Mature forms: banana-shaped or rounded; chromatin: single, well defined; pigment: scattered, coarse, rice-grain like; pink extrusion body sometimes present. Eroded forms with only chromatin and pigment often seen.</p>
 <p>Size: small to large; number: few to moderate; shape: broken ring to irregular forms common; chromatin: single, occasionally two; cytoplasm: irregular or fragmented; mature forms: compact, dense; pigment: scattered, fine.</p>	 <p>Size: large; number: few to moderate; mature forms: 12-24 merozoites, usually 16, in irregular cluster; pigment: loose mass.</p>	 <p>Immature forms difficult to distinguish from mature trophozoites. Mature forms: round, large; chromatin: single, well defined; pigment: scattered, fine. Eroded forms with scanty or no cytoplasm and only chromatin and pigment present.</p>
		<p>Young, growing trophozoites and/or mature gametocytes usually seen.</p>
		<p>All stages seen; Schüffner's stippling in 'ghost' of host red cells, especially at film edge.</p>







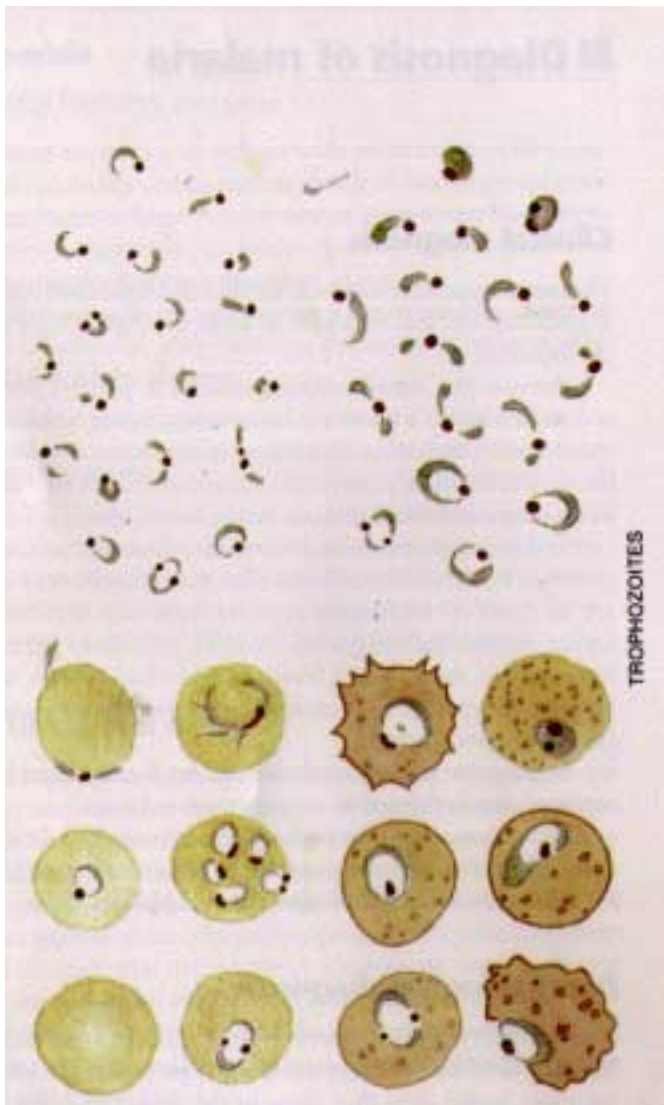
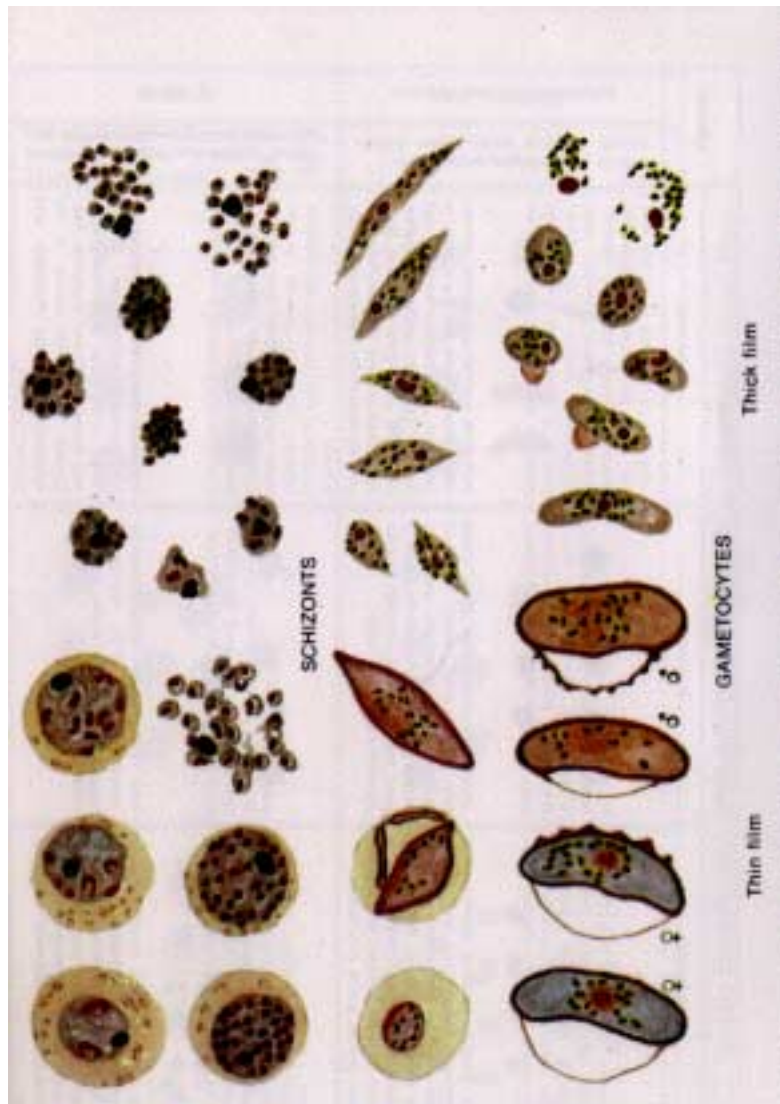<i>P. ovale</i>	<i>P. malariae</i>
<p>All stages seen, prominent Schüffner's stippling in 'ghost' of host red cells, especially at film edge.</p>	<p>All stages seen.</p>
 <p>Immature forms difficult to distinguish from mature trophozoites. Mature forms: round, may be smaller than <i>P. vivax</i>; chromatin single, well defined; pigment: scattered, coarse. Eroded forms with only chromatin and pigment present.</p>	 <p>Immature and certain mature forms difficult to distinguish from mature trophozoites. Mature forms: round, compact; chromatin: single, well defined; pigment: scattered, coarse, may be peripherally distributed. Eroded forms with only chromatin and pigment present.</p>
 <p>Size: rather like <i>P. malariae</i>, number: few, mature forms: 4-12 merozoites, usually 8, in loose cluster; pigment: concentrated mass.</p>	 <p>Size: small, compact; number: usually few, mature forms: 6-12 merozoites, usually 8, in loose cluster; some apparently without cytoplasm; pigment: concentrated.</p>
 <p>Size: may be smaller than <i>P. vivax</i>, number: usually few; shape: ring to rounded, compact forms; chromatin: single, prominent; cytoplasm: fairly regular, fleshy; pigment: scattered, coarse.</p>	 <p>Size: small; number: usually few; shape: ring to rounded, compact forms; chromatin: single, large; cytoplasm: regular, dense; pigment: scattered, abundant, with yellow tinge in older forms.</p>

Fig. 14. Species identification of malaria parasites in Giemsa-stained thick blood films

Fig. 15. Appearance of *P. falciparum* parasite stages in Giemsa-stained thin and thick blood films





Common errors in diagnosis and management

The common errors in the diagnosis and management of severe malaria are listed below.

Errors in diagnosis

Failure to think of malaria in a patient with either typical or atypical illness

Failure to elicit a history of exposure (travel history) – including travel within a country with variable transmission

Misjudgement of severity

Failure to do a thick blood film in a non-immune patient

Failure to identify *P. falciparum* in a dual infection with *P. vivax* (the latter may be more obvious)

Missed hypoglycaemia

Failure to diagnose other associated infections (bacterial, viral, etc.)

Misdiagnosis (e.g. influenza, viral encephalitis, hepatitis, scrub typhus, etc.)

Failure to recognize respiratory distress (metabolic acidosis)

Failure to carry out an ophthalmoscopic examination for the presence of papilloedema, and retinal haemorrhages in adults.

Errors in management

Inadequate nursing care (see page 10)

Delay in starting antimalarial therapy

Use of inappropriate therapy:

- chloroquine in areas of resistance
- unjustified withholding of an antimalarial drug (see page 7)

- dosage not correctly calculated
- inappropriate route of administration (see inside front cover flap)
- unjustified cessation of treatment
- failure to prevent cumulative effects of antimalarial drugs
- failure to switch patients from parenteral to oral therapy as soon as they can take oral medication
- unnecessary continuation of chemotherapy beyond the recommended length of treatment (see inside front cover flap)
- use of unproven and potentially dangerous ancillary treatment (see page 15)
- failure to review antimalarial treatment in a patient whose condition is deteriorating

Errors of fluid and electrolyte replacement (see pages 18 and 19)

- failure to control the rate of intravenous infusion

Failure to elicit a history of recent chemotherapy

Failure to identify or treat metabolic acidosis

Unnecessary endotracheal intubation

Unduly delayed endotracheal intubation (where this is indicated and possible)

Failure to control convulsions

Failure to recognize minor (“subtle”) convulsions

Failure to recognize and treat severe anaemia

Delay in considering obstetrical intervention in late pregnancy

Failure to recognize and manage pulmonary oedema

Undue delay in starting peritoneal dialysis or haemodialysis

Failure to pass a nasogastric tube to prevent aspiration pneumonia

Failure to give antibiotics as a covering procedure if the decision is made to delay lumbar puncture.

■ Selected further reading

Basic malaria microscopy. Part I: Learner's guide. Part II: Tutor's guide. Geneva, World Health Organization, 1991.

International travel and health. Vaccination requirements and health advice. Geneva, World Health Organization (updated annually).

WHO model prescribing information: drugs used in parasitic diseases, 2nd ed. Geneva, World Health Organization, 1995.

Antimalarial drug policies: data requirements, treatment of uncomplicated malaria and management of malaria in pregnancy. Report of an informal consultation, Geneva 14-18 March 1994. Geneva, World Health Organization, 1994 (unpublished document WHO/MAL/94.1070; available on request from Communicable Disease Prevention and Control, World Health Organization, 1211 Geneva 27, Switzerland).

WHO. Severe falciparum malaria, 3rd ed. *Transactions of the Royal Society of Tropical Medicine and Hygiene* (in press)

Gilles HM, Warrell DA, eds. *Bruce-Chwatt's essential malariaology*, 3rd ed. London, Edward Arnold, 1996.

■ Notes on antimalarial drugs

Quinine

At present, quinine remains the drug of choice for the treatment of severe and complicated malaria in most parts of the world. It should always be given by rate-controlled infusion, **never** by bolus (“push”) intravenous injection. It may also be given intramuscularly diluted to 60–100 mg/ml. Quinine is safe in pregnancy.

Mild side-effects are common, notably cinchonism (tinnitus, hearing loss, dizziness, nausea, uneasiness, restlessness and blurring of vision); serious cardiovascular and neurological toxicity is rare. Hypoglycaemia is the most serious frequent adverse side-effect. In suspected quinine poisoning, activated charcoal given orally or by nasogastric tube accelerates elimination.

Artemisinin

Artemisinin and its derivatives may be administered intrarectally. Suppository formulations of artemisinin, developed originally in China, have proved highly effective in clinical trials in adults and children with severe malaria in Viet Nam in dosages ranging from 10 to 40 mg/kg of body weight. However, more studies are needed to determine the optimal dosage and schedule of administration. The therapeutic response has been as rapid as that following parenteral administration of artesunate and artemether, and the suppositories have been well tolerated. Artemisinin derivatives do not induce hypoglycaemia in pregnancy although there is still very little information on their use in pregnancy. To date there is no reason to withhold these drugs from pregnant women with severe malaria.

Artesunate

Artesunate is now becoming more widely used and is available in oral, intramuscular and intravenous formulations. It is rapidly absorbed with an accelerated parasite clearance time when compared with quinine. The drug is well tolerated with no attributable local or systemic adverse effects. Studies evaluating a suppository formulation of artesunate gel in a gelatin-covered capsule (rectocap) are currently in progress in which adult patients with severe malaria have been treated with 200-mg rectocaps in a total dose ranging from 1200 to 1600 mg over 60–72 hours. However, more studies are needed to determine the optimal dosage and schedule of administration.

Artemether

Artemether is available in oral and intramuscular formulations. Its efficacy, side-effects and availability are similar to artesunate except that the parenteral formulation is oil-based and may be inadequately or erratically absorbed following intramuscular injection in severely ill patients. Studies evaluating the intrarectal administration of the parenteral formulation of artemether in a dosage of 10 mg/kg of body weight are currently in progress.

Sulfadoxine–pyrimethamine (500 mg + 25 mg)

Sulfadoxine–pyrimethamine should preferably not be given in the first trimester of pregnancy. Sulfonamides should not be given directly to neonates because of the risk of kernicterus, but sulfonamide treatment of a lactating woman does not pose a threat to her breastfed neonate unless there is jaundice, prematurity or G6PD deficiency. Theoretically,

there might be a risk of kernicterus if sulfonamides were administered in late pregnancy, just before delivery; however, there has been no documented case of this complication. An intramuscular preparation exists and may be useful for treatment of severe malaria if quinine or artemisinin derivatives are not available or cannot be given safely. When the contra-indications to the use of this drug are respected, and when this drug combination is used as a single-dose treatment for malaria in the prescribed manner, severe reactions are rare.

Chloroquine

Chloroquine in tablet form is still the most widely prescribed antimalarial drug in the tropics. Despite parasite resistance, it provides symptomatic relief and reduces morbidity and mortality in many endemic areas where resistance is predominantly RI or RII. Its safe use in severe malaria is restricted to Central America where parasite resistance has not been demonstrated. In severe disease, chloroquine, like quinine, should always be given by slow, rate-controlled intravenous infusion and **never** by bolus (“push”) injection. It can also be given intramuscularly or subcutaneously at a lower dosage than that recommended for intravenous infusion (see inside front cover flap). Oral therapy should be substituted as soon as possible; crushed chloroquine tablets can be given by nasogastric tube if injection is not possible. Immediate side-effects include nausea, vomiting, headache, uneasiness, restlessness, blurred vision, hypotension and pruritus. Acute chloroquine poisoning is manifested by coma, convulsions, dysrhythmias and hypotension.

Mefloquine

Mefloquine is effective against all malarial species including multidrug-resistant *P. falciparum*. Structurally, it resembles quinine. Naturally resistant parasite populations have been reported in various parts of the tropics. It is available **only in tablet form**. Toxic effects include nausea, abdominal discomfort, vertigo, insomnia and malaise. Acute psychosis and a transient encephalopathy with convulsions are serious but generally short-lived side-effects. In severe malaria a post-malarial neurological syndrome has been reported in Viet Nam, where mefloquine was used to complement parenteral therapy (with artesunate and artemether).

Annex 2

The Glasgow coma scale

		Score
Eyes open:	spontaneously	4
	to speech	3
	to pain	2
	never	1
Best verbal response:	oriented	5
	confused	4
	inappropriate words	3
	incomprehensible sounds	2
	none	1
Best motor response:	obeys commands	5
	localizes pain	4
	flexion to pain	3
	extension to pain	2
	none	1
	Total	3–14

A state of unrousable coma is reached at a score of <10.

This scale can be used repeatedly to assess improvement or deterioration.

Annex 3

A coma scale for children

The following coma scale – the “Blantyre coma scale” – modified from the widely used Glasgow coma scale (1974), is applicable to children, including those who have not learned to speak.

		Score
Best motor response:	localizes painful stimulus ^a	2
	withdraws limb from pain ^b	1
	nonspecific or absent response	0
Verbal response:	appropriate cry	2
	moan or inappropriate cry	1
	none	0
Eye movements:	directed	
	(e.g. follows mother’s face)	1
	not directed	0
Total		0–5

A state of unrousable coma is reached at a score of <3.

This scale can be used repeatedly to assess improvement or deterioration.

^a Rub knuckles on patient’s sternum.

^b Firm pressure on thumbnail bed with horizontal pencil.

Annex 4

Cannulating the femoral vein

In a shocked adult or child with hypotension and collapsed peripheral veins, the femoral veins may provide the only possibility for venous access.

Anatomy

The femoral vein lies immediately medial to the femoral artery at about the midpoint of the inguinal (Poupart's) ligament at the groin (Fig. 16).

Method

With the patient lying supine with the right thigh slightly abducted and externally rotated, locate the femoral arterial pulse at the groin with the index and middle fingers of your left hand. Clean the skin thoroughly with alcohol or iodine and, with full sterile precautions, mount the cannula with its introducing needle on a syringe. Puncture the skin just medial to the femoral artery, just below the groin crease, and, with the cannula assembly at an angle of 45° , advance gently, aspirating repeatedly until the vein is entered and blood drawn back. If the needle meets firm resistance withdraw, millimetre by millimetre, aspirating each time until blood can be drawn back freely with the syringe. Once you are confident that the needle tip is in the lumen of the vein, flatten the angle slightly and advance the cannula into the vein. Secure the cannula in place with a gauze pad and sticking plaster. Alternatively, the left femoral vein may be cannulated; this is more convenient if the operator is left-handed.

Caution

Infection and thrombosis of the femoral vein are serious complications. Avoid leaving a femoral cannula in place for longer than is absolutely necessary.

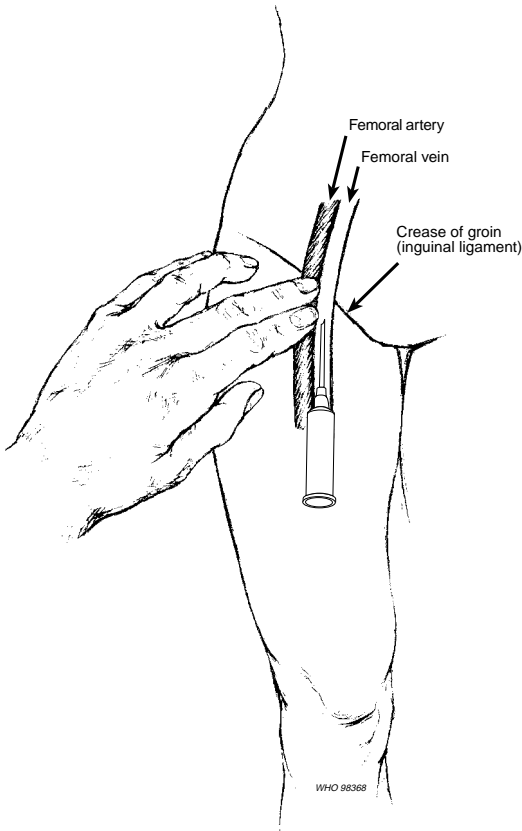


Fig. 16. Location of the femoral arterial pulse and site for insertion of a femoral venous cannula

Annex 5

Setting up an intra-osseous infusion in children

When intravenous access has proved impossible, an intra-osseous infusion can be life-saving. It can be used to administer anything that would normally be given intravenously, i.e. fluids, whole blood, packed cells, drugs.

Equipment

- Alcohol swabs.
- A small syringe and fine needle for giving local anaesthetic (unnecessary if patient is comatose).
- An 18-gauge needle with trochar (special needles are made for intra-osseous infusion). Alternatively a bone-marrow aspiration needle, or even a standard 17–21 gauge disposable needle, can be used, with care.
- An IV bottle and drip-set, or 50-ml syringe containing fluid for infusion.
- Local anaesthetic, e.g. 1% lidocaine.

Procedure (with full sterile precautions)

- Choose a point for insertion of the infusion needle in the middle of the wide flat part of the tibia, about 2 cm below the line of the knee joint (see Fig. 17).
- Do not use a site of trauma or sepsis.
- If the patient is conscious, infiltrate the skin and underlying periosteum with local anaesthetic.
- With the needle at right angles to the skin, press firmly with a slight twisting motion until the needle enters the marrow cavity with a sudden “give”.

- Attach a 5-ml syringe and aspirate to confirm that the position is correct. The aspirate can be used for blood films, blood culture and blood glucose measurement.
- The infusion needle should be held in place using sticking plaster (or a plaster of Paris cast, as with scalp vein infusions) and the child's mother or carer entrusted with holding the leg.
- You can place an infusion in each leg, either simultaneously or in sequence, if necessary.
- An alternative site for an intra-osseous infusion is the antero-lateral surface of the femur, 2–3 cm above the lateral condyle.
- An infusion allowed to drip through the needle in the usual way (by gravity) may go very slowly. For urgent administration use a 50-ml syringe to push in the required fluid in boluses.

Possible complications

Sepsis. Do not leave an intra-osseous line in one site for more than 6–8 hours. After this time sepsis is increasingly likely to develop.

Compartment syndrome. If the needle is allowed to pass entirely through the tibia, fluid may be infused into the posterior compartment of the leg causing swelling and eventually impairing circulation. Check circulation in the distal leg at intervals.

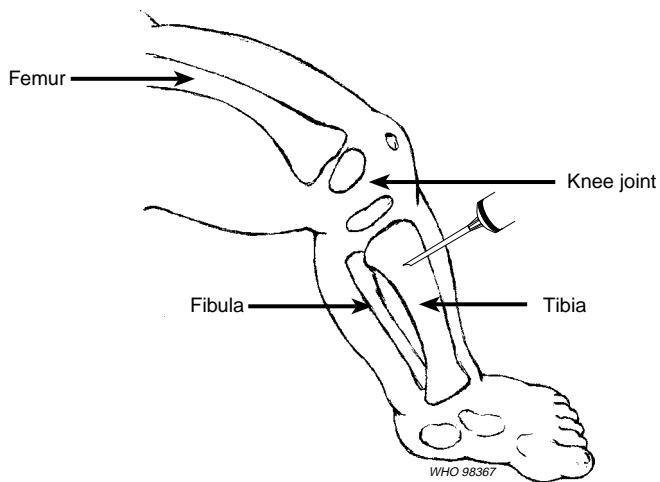


Fig. 17. Site for insertion of an intra-osseous infusion in the tibia

Annex 6

Measurement of central venous pressure

Jugular venous pressure is a clinical measure of central venous pressure (Fig. 18). It is the height of the pulsating column of blood in the great veins draining into the right atrium and, in malaria, is a useful measure of over- or under-hydration (hyper- or hypovolaemia).

Jugular venous pressure is the vertical distance, measured in cm, between the venous pulsation in the neck and the sternal angle (junction of the second rib with the sternum) when the patient is propped up on pillows at 45° to the horizontal. In this position, the sternal angle marks the level of the right atrium. The height of the jugular venous pressure is normally 4–5 cm. In order to measure it, the patient should be made as comfortable and relaxed as

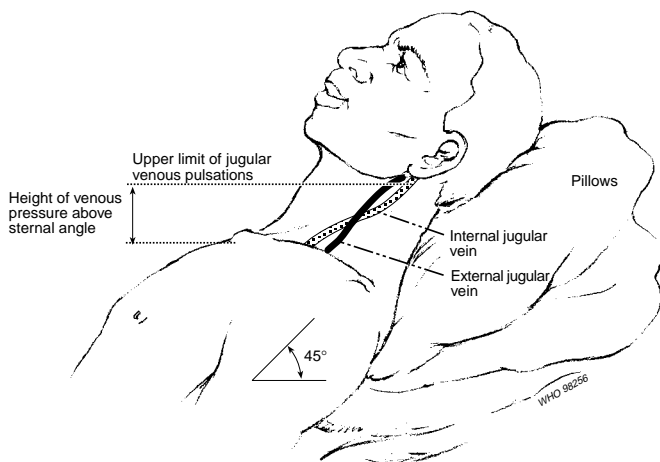


Fig. 18. Measurement of the height of the jugular venous pressure

possible. It is difficult or impossible to identify venous pulsation if the neck muscles are contracted. Try to achieve good (oblique) lighting of the neck. Look for the jugular venous pulse in the internal jugular vein or its external jugular tributaries on both sides of the neck with the patient's chin tilted up and slightly away from you. The following characteristics help to distinguish jugular venous pulsation from carotid arterial pulsation. The jugular venous pulse:

- has two waves for every single carotid artery pulsation; make this comparison by gently palpating the carotid pulse on the opposite side of the neck;
- falls with inspiration and rises with expiration (except where there is cardiac tamponade);
- can be obliterated by pressing firmly but gently with the back of the index finger placed horizontally just above the clavicle at the root of the neck;
- may be visible only when the patient is lying flat (in cases of hypovolaemia) or when the patient is sitting upright at 90° (for example, in severe congestive cardiac failure);
- is usually impalpable.

Do not be misled by what appears to be a high venous pressure but is just a non-pulsatile column of blood trapped in the external jugular vein. To double-check, press firmly and gently just above the clavicle so as to trap blood in the external jugular veins. When the pressure is suddenly released, the engorged veins should collapse immediately unless there is high central venous pressure. The jugular venous pressure cannot be assessed when there is gross tricuspid valve regurgitation.

In seriously ill patients, or those in whom clinical assessment is considered inaccurate, a central venous catheter should be inserted.

Global status of chloroquine resistance

Among the countries where falciparum malaria is endemic, only those of Central America have not reported resistance of *Plasmodium falciparum* to chloroquine. Chloroquine resistance of various levels is now common in practically all endemic countries of Africa and, especially in eastern Africa, poses increasing problems for the provision of adequate treatment. In western and middle South Asia, as well as in Malaysia, the Philippines and Oceania, levels of chloroquine resistance are variable.

In view of the global distribution of chloroquine resistance, except for countries of Central America, **chloroquine should not be used to treat severe falciparum malaria.**

Summary of the management of severe falciparum malaria

In all cases an appropriate antimalarial drug should be started immediately and complications managed appropriately as below.

Complication and immediate management

1. Coma (cerebral malaria)

Maintain airway; nurse on side; exclude other treatable causes of coma (e.g. hypoglycaemia, bacterial meningoenzephalitis). Avoid harmful adjuvant treatments such as corticosteroids, heparin and epinephrine (adrenaline).

2. Convulsions

Maintain airway; treat with diazepam given intravenously (0.15 mg/kg of body weight) or intrarectally (0.5 mg/kg of body weight), or intramuscular paraldehyde injection (0.1 ml/kg of body weight). Paraldehyde should, if possible, be given from a glass syringe. A disposable plastic syringe may be used, provided that the injection is given immediately the paraldehyde is drawn up and that the syringe is never reused.

3. Severe anaemia

Transfuse screened fresh whole blood or packed cells.

4. Acute renal failure

Exclude dehydration; maintain strict fluid balance; carry out dialysis if indicated.

5. Hypoglycaemia

Measure blood glucose, give 50% dextrose injection 50 ml (1 ml/kg of body weight for children) followed by 5% or 10% dextrose infusion.

6. Metabolic acidosis

Exclude or treat hypoglycaemia, hypovolaemia and Gram-negative septicaemia. Give isotonic saline 20 ml/kg of body weight rapidly or screened whole blood 10 ml/kg of body weight over 30 minutes if haemoglobin is <5g/dl.

7. Acute pulmonary oedema

Prevent by avoiding excessive rehydration. Prop patient up; give oxygen. If pulmonary oedema is due to over-hydration, stop intravenous fluids, give a diuretic (furosemide (frusemide) 40 mg intravenously) and withdraw 3 ml/kg of blood by venesection into a donor bag.

8. Shock, algid malaria

Suspect Gram-negative septicaemia; take blood samples for culture. Give parenteral antimicrobials; correct haemodynamic disturbances.

9. Spontaneous bleeding and coagulopathy

Transfuse screened fresh whole blood or clotting factors; give vitamin K, 10 mg intravenously.

10. Hyperpyrexia

Give antipyretic (paracetamol 15 mg/kg of body weight) and use tepid sponging and fanning.

11. Hyperparasitaemia

Give initial dose of parenteral antimalarial therapy; consider exchange transfusion if there are other signs of severity.

12. Malarial haemoglobinuria

Continue antimalarial treatment; transfuse screened fresh blood if needed.

13. Aspiration pneumonia

Give parenteral antimicrobials; change position of patient; give physiotherapy; give oxygen.

Malaria continues to be a major health problem in many parts of the world, with over 2400 million people in some 100 countries at risk of infection. Delay in treating *P. falciparum* – the species of parasite that can cause severe forms of the disease – may result in rapid deterioration in the patient's condition, together with the development of a number of life-threatening complications.

This handbook is an updated edition of *Management of severe and complicated malaria*, providing new and revised practical guidance on the diagnosis and management of severe falciparum malaria. After outlining the general nursing care needed by these patients, it considers in turn the possible complications, including coma, convulsions, severe anaemia, acidosis, renal failure, hypoglycaemia, and pulmonary oedema, and gives specific and concise advice on their management. While intended primarily for clinical professionals and other responsible health staff working in hospitals and health centres with inpatient facilities in malaria-endemic countries, it will also be of practical use to physicians in non-endemic areas, who are increasingly having to deal with patients infected during visits to malarious areas.

Price: Sw. fr. 15.–

Price in developing countries: Sw. fr. 10.50

ISBN 92 4 154523 2